

# MEASUREMENT OF THE TRICUSPID AND THE MITRAL VALVE IN ADULT HUMAN HEART: A CADAVERIC STUDY

*Lama CP, Pradhan A, Chalise U, Dhungel S, Ghosh SK*

Department of Anatomy, Nepal Medical College and Teaching Hospital, Attarkhel, Gokarneshwor-8, Kathmandu, Nepal

## ABSTRACT

The human heart valve is an integral structure and the valvular heart disease is one of the most common disease of the heart. Such cardiac disease require repair of the valve and valve replacement surgery where the patient's diseased valve is replaced by a prosthetic valve. The aim of this study was to measure the annular circumferences and diameters of tricuspid and mitral valves in cadavers. A morphometric study was conducted in Department of Anatomy at Nepal Medical College and Teaching Hospital where total 50 cadaveric hearts were taken up for the study. The tricuspid and the mitral valves were exposed by dissection method. Measurements were taken by using a thread and a digital vernier caliper and obtained data were analysed by using SPSS-16. The mean, frequency and standard deviation of circumferences and diameters of both tricuspid and the mitral valves were analysed and were found as (a) The mean annular circumference of tricuspid valve was  $11.22 \pm 0.20$  cm (b) The mean diameter of tricuspid valve was  $2.33 \pm 0.04$  cm. (c) The mean annular circumference of mitral valve was  $9.22 \pm 1.49$  cm (d) the mean diameter of mitral valve was  $2.01 \pm 0.27$  cm. There were few literatures available on the study of cadaveric heart valves in Nepal thus this study will provide a guideline to the clinicians, radiologists and also to cardiothoracic surgeons performing various valve surgeries to assess the prosthetic valve of appropriate size and to the anthropologists also to maintain a standardized data on cardiac valves as well.

## KEYWORDS

Mitral valve annular circumference, mitral valve diameter, tricuspid valve annular circumference, tricuspid valve diameter

## CORRESPONDING AUTHOR

Dr. Chhiring Palmu Lama,  
Department of Anatomy,  
Nepal Medical College and Teaching Hospital,  
Attarkhel, Gokarneshwor-8, Kathmandu, Nepal  
Email: drcpalmu@yahoo.com

## INTRODUCTION

The human heart which lies in the middle mediastinum consists of four chambers and are provided with openings for inflow and outflow of blood. These openings in the heart are guarded by valves to maintain the unidirectional flow of blood. There are two atrioventricular valves, the tricuspid and the mitral valve. The atrioventricular valvular complex in both the left and right ventricles consist of the orifice and its associated annulus, cusps, chordae tendinae and papillary muscles.<sup>1</sup> The mitral valve term was first introduced by Andreas Vesalius to describe the left atrioventricular valve due to its resemblance to the bishop's cap. (mitre) The other two valves present in the heart are pulmonary and aortic valves. All these valves should be healthy and intact for proper functioning of the heart. Because of the improved diagnostic procedure available these days it was observed that many of the cardiac problems are due to abnormal size of these valves and the commonly affected heart valves are tricuspid and mitral valves.<sup>2</sup> The size of these valves and their openings are also affected by various congenital conditions and diseases in the form of stenosis, incompetence and prolapse of the leaflets. Hence the dimensions of these valves are of interest to the clinicians and surgeons to assess the exact mechanical reason for valvular insufficiency.<sup>3</sup> The affected heart valves require repair or valve replacement surgery. The valve replacement is a complex surgical procedure where the patient's diseased valve is replaced with a prosthetic valve.<sup>4</sup>

Presently the repair is done by valves of different synthetic material or by biological tissue as follows  
 1. Homograft (Allograft) – The human cadaveric valves are transplanted in the diseased person.  
 2. Autograft –The patient's own body's fascia lata or pericardium is taken and transplanted.  
 3. Heterograft (Xenograft) – Bovine pericardial tissue is taken and transplanted in the diseased person.<sup>5</sup>

The exact knowledge of anatomy and the measurement of valve rings and cusps are needed for the success of such procedure. Hence the present study was undertaken to find out the annular circumference and diameter of both the mitral and tricuspid valves which will help the cardiothoracic surgeons as well as the prosthetic valve manufacturers for the accurate estimation of valve size and can also be used as an important tool in the anthropological studies as well.<sup>6</sup>

## MATERIALS AND METHODS

A morphometrical study of 50 cadaveric heart valves were conducted in Department of Anatomy at Nepal Medical College and Teaching Hospital (NMCTH) by dissection method. The cadaveric hearts without any apparent gross morphological

abnormalities were included excluding the hearts having calcified valves with gross anomalies. To expose a tricuspid valve a vertical incision was made along the right border of the heart from the

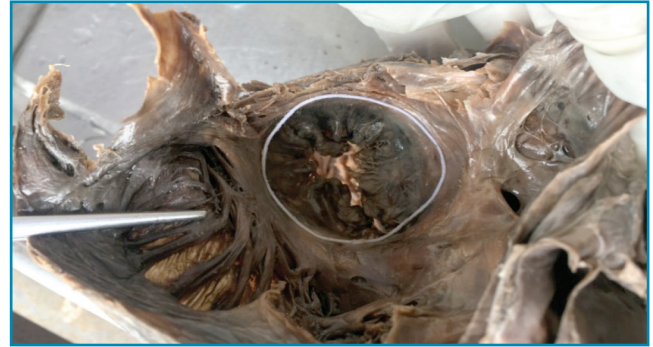

Fig. 1: Measurement of annular circumference of tricuspid valve

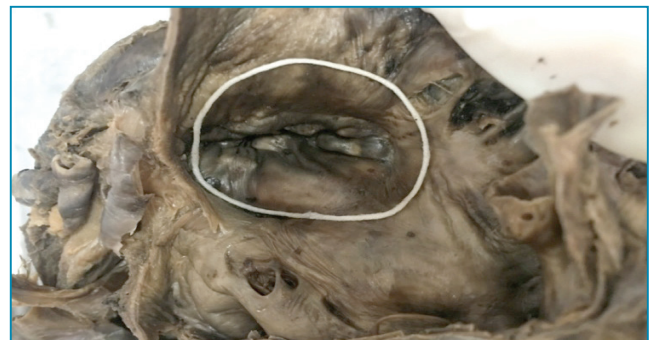

Fig. 2: Measurement of annular circumference of mitral valve

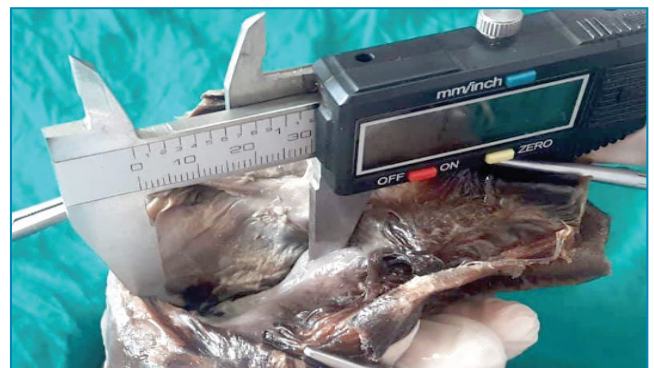

Fig. 3: Measurement of the diameter of tricuspid valve by using a digital vernier caliper

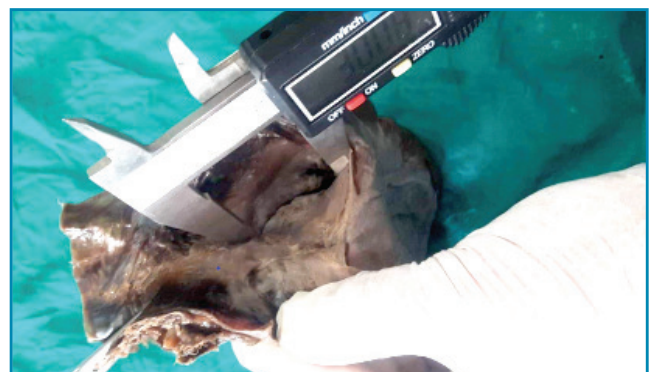


Fig. 4: Measurement of the diameter of mitral valve by using a digital vernier caliper

entry point of superior venacava till the entry of inferior venacava into the right atrium and from the lower end of this incision another horizontal incision was made up to the entry point of coronary sinus into the right atrium. The muscular flaps were raised, blood clots were removed and thorough wash was given. The interior of the right atrium was observed for any obvious deformity and the tricuspid valve was exposed. For the exposure of mitral valve an incision was made along the left border of the heart from left auricle up to the apex. The ventricle was then opened up and the mitral valve was exposed and cavity was thoroughly washed.<sup>25</sup> The circumference of the tricuspid and the mitral valve orifices were measured with the help of thread. The measured thread was further placed along the boundary of the annulus confirming to its shape and the length of the thread was measured using a ruler after making it straight. (Fig.1 and 2) Similarly, the diameter of the valves were measured using

a digital vernier caliper. (Fig. 3 and 4)

The mean value, frequency and the standard deviation were analyzed by using SPSS version 16 and were presented in the tabular form.

## RESULTS

Fifty cadaveric hearts were included in the study. The annular circumferences and diameters of the tricuspid valves measured have been illustrated in Table 1. The minimum annular circumference of tricuspid valve was 8.5 cm and the maximum annular circumference of tricuspid valve was 13.0 cm which have also been shown in Table 1. Table 2 showed the mean annular circumference of tricuspid valve as  $11.22 \pm 0.20$  cm and the mean diameter of annulus of tricuspid valve as  $2.33 \pm 0.04$  cm. The annular circumference of tricuspid valve in the range of 10.6 – 11.5 cm was found in

Table 1: Annular circumference and diameter of tricuspid valves

S.N.	Annular circumference of tricuspid valve (cm)	Diameter of annulus of tricuspid valve (cm)	S.N.	Annular circumference of tricuspid valve (cm)	Diameter of annulus of tricuspid valve (cm)
1	8.5	1.98	26	13	2.86
2	9.5	1.99	27	12.5	2.76
3	9	2.09	28	12.5	2.76
4	10	2.33	29	13	2.87
5	13	2.87	30	9	1.99
6	9	1.98	31	11	2.40
7	10	1.98	32	13	2.86
8	10.5	1.98	33	12	2.48
9	9	1.96	34	13	2.72
10	9.5	2.12	35	12.5	2.47
11	11.5	2.31	36	11	2.40
12	10	2.15	37	12	2.47
13	8.5	1.98	38	11.5	2.33
14	10.5	2.23	39	12	2.48
15	9	2.09	40	13	2.48
16	10	2.12	41	13	2.23
17	11	2.23	42	12	2.48
18	11.5	2.18	43	11	2.40
19	11	2.15	44	12	2.40
20	11.5	2.13	45	13	2.79
21	12.5	2.31	46	9	1.98
22	11	1.96	47	11.5	2.48
23	13	2.79	48	12	2.48
24	12	2.23	49	13	2.72
25	12	2.31	50	11	2.18

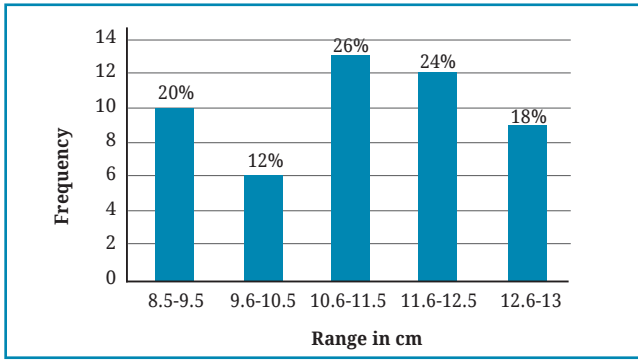


Fig. 5: Frequency range of annular circumference of tricuspid valve in cm

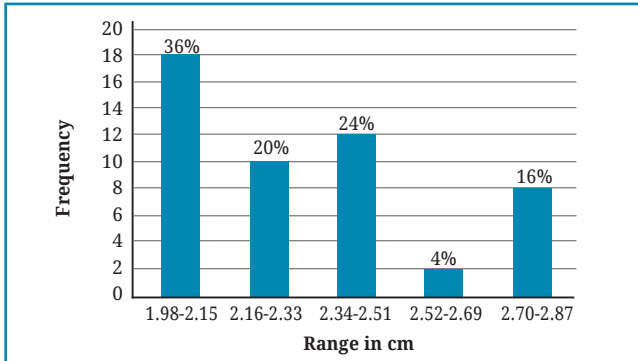


Fig. 6: Frequency range of annular diameter of tricuspid valve in cm

maximum number of specimens (26%) followed by 11.6 – 12.5 cm (24%), 8.5-9.5 cm (20%), 12.6 – 13.0 cm (18%), 9.6- 10.5 cm (12%) which have been shown in Fig. 5. Table 1 also shows the minimum and the maximum diameters of annulus of tricuspid valves which were found to be 1.98 cm and 2.87 cm respectively. The diameter of annulus of tricuspid valve in the range of 1.98 – 2.15 cm was noted in maximum number of specimens (36%) followed by 2.34 – 2.51 cm (24%), 2.52 – 2.69 cm (20%), 2.70-2.87 cm (16%), 2.52-2.69 cm (4%) which have been shown in Fig. 6.

Table 2: Mean of annular circumference and diameter of tricuspid valve

Total no. of specimens (n = 50 )	Mean annular circumference of tricuspid valve (cm) (Mean ± SD )	Mean diameter of annulus of tricuspid valve (cm) (Mean ± SD)
50	11.22 ± 0.20	2.33 ± 0.04

The annular circumferences and diameters of the mitral valves taken have been illustrated in Table 3. The minimum circumference of mitral valve was 7.5 cm and the maximum circumference of

Table 3: Annular circumference and diameter of mitral valves

S.N.	Annular circumference of mitral valve (cm)	Diameter of annulus of mitral valve (cm)	S.N.	Annular circumference of mitral valve (cm)	Diameter of annulus of mitral valve (cm)
1	7.5	1.61	26	8.5	1.80
2	8	1.84	27	10	1.96
3	7.5	1.76	28	11	2.00
4	8	1.83	29	10	1.97
5	8.5	1.85	30	9	1.76
6	9	1.84	31	10	1.83
7	10	1.80	32	8	1.84
8	8.5	1.84	33	8	1.85
9	8	1.68	34	11	2.08
10	8.5	1.80	35	10	2.28
11	10	2.28	36	8.5	1.97
12	10	2.13	37	9	1.96
13	8.5	2.00	38	8.5	1.85
14	8.5	1.89	39	8	1.84
15	10	2.28	40	10	1.99
16	11	2.72	41	10.5	2.07
17	9.5	1.94	42	9	1.95
18	11	2.50	43	10	2.13
19	9	2.07	44	8	1.96
20	10	2.03	45	8	1.94
21	11	2.72	46	10.5	2.44
22	9.5	2.21	47	9	1.89
23	10	1.99	48	8	2.00
24	9	2.08	49	8	1.96
25	11	2.50	50	9	2.03

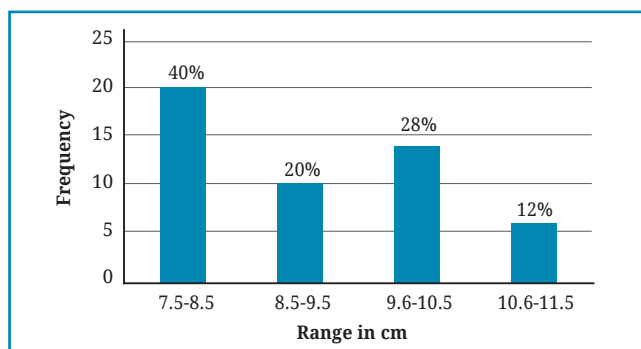


Fig. 7: Frequency range of annular circumference of mitral valve in cm

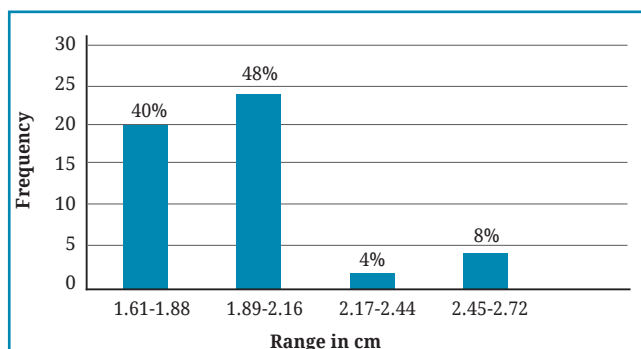


Fig. 8: Frequency range of annular diameter of mitral valve in cm

mitral valve was 11.0 cm (Table 3). Table 4 shows the mean annular circumference of mitral valve and the mean diameter of annulus of mitral valve as  $9.22 \pm 1.49$  cm and  $2.01 \pm 0.27$  cm respectively. In maximum number of specimens the annular circumference of mitral valve ranged from 7.5 – 8.5 cm (40%) followed by 9.6 – 10.5 cm (28%), 8.6 – 9.5 cm (20%), 10.6-11.0 cm (12%) as shown in Fig. 7. The minimum diameter of annulus of mitral valve was 1.61 cm and the maximum diameter of annulus of mitral valve was 2.72 cm as shown in Table 3. Fig. 8 shows the diameter of annulus of mitral valve which was maximum in the range of 1.89 – 2.16 cm (48 %) followed by the range of 1.61- 1.88 cm (40%), 2.45 - 2.72 cm (8%), and 2.17 – 2.44 cm (4%).

Table 4: Mean of annular circumference and diameter of mitral valve

Total no. of specimens (n = 50)	Mean annular circumference of mitral valve in cm (Mean $\pm$ SD)	Mean diameter of annulus of mitral valve in cm (Mean $\pm$ SD)
50	$9.22 \pm 1.49$	$2.01 \pm 0.27$

## DISCUSSION

The circumference and diameter of the annulus of tricuspid and the mitral valves of 50 cadavers were studied in Department of Anatomy of Nepal Medical College in a mixed Nepalese population.

Though many researchers have reported these dimensions in various populations, very few literatures are available on these dimensions in Nepalese population. Hence the data of the present study can be taken as an useful guide in practice. Various observations have been made on the cardiac valves by using different methods like dissection, 2D or 3D – echocardiography and image J software. The findings are found to be variable depending upon the method used. In the present study we first dissected in formalin fixed cadavers and measured the circumference by thread (Fig. 1 and 2) and diameter by a digital vernier caliper (Fig. 3 and 4). In dissection method some studies have also been conducted in fresh cadaveric hearts other than the formalin fixed hearts. The morphometric study of the tricuspid valve has also been conducted in human fetal cadavers to provide a database for the dimensions of right atrioventricular orifice in human fetuses of different gestational age.<sup>24</sup>

### Dimensions of Tricuspid valve

According to Gray's Anatomy the mean value of tricuspid valve circumference is 10.8 cm in females and 11.4 cm in males.<sup>1</sup> In the present study all male cadavers were included. The tricuspid valve orifice was best seen from the atrial aspect and the mean circumference of tricuspid valve annulus was found to be  $11.22 \pm 0.20$  cm in the present study (Table 2) which was very similar to the study conducted in Poland by Skwarek M.<sup>12</sup> Since the size of the circumference and diameter varies (Table 1), we observed an annular circumference between 10.6 – 11.5 cm in the maximum number of specimens (26%) and similar data were also provided by Kalyani<sup>15</sup> and Ilankathir<sup>25</sup> among Indian population.

The 2<sup>nd</sup> most common tricuspid circumference was between 8.5 – 9.5 cm (20 %) which was also reported by some other observer,<sup>24</sup> while the values obtained by some authors were found to be higher.<sup>11,27</sup> The difference in these values could be because of the different method applied by them where they used the image J software.

The mean diameter of annulus of tricuspid valve in present study was  $2.33 \pm 0.04$  cm (Table 2) which was lower than the values obtained by Dwedi<sup>24</sup> where they measured the diameter using 2D-echocardiography during the cardiac cycle. Among the several morphometric studies of heart valves by dissection method this parameter was referred only in few literatures compared to other dimensions of the heart valves.

### Dimensions of mitral valve

According to Gray's Anatomy the mean circumference of mitral valve ranged from 7.2 -9 cm.<sup>1</sup> This value was similar with the mean value of present study (Table 4). The annulus of the valve is not a simple fibrous ring, but is made up of fibrocollagenous elements from which the cusps take origin. The mean annular circumference

of mitral valve in present study was  $9.22 \pm 1.49$  cm (Table 4) which was similar with the values of many other observers.<sup>14,16,17,26</sup> and higher than the value of Andrade where the fresh cadaveric hearts were included in the study.<sup>11</sup>

This difference is probably because in fresh cadavers the elasticity of the soft tissue is still maintained resulting in smaller dimension. The present value was found to be lower than the observations by Du Plessis<sup>3</sup> and Ormiston<sup>9</sup> where the studies were conducted among Africans and Americans. The higher range of their study could be due to the physical attributions of those populations. In the present study a circumference between 7.5 – 8.5 cm was found in maximum number of specimens (40%) which was similar with the values reported by many other observers.<sup>13,19,20,25</sup>

The mean diameter of mitral valve in present study was  $2.01 \pm 0.27$ cm (Table 4) which was similar with the studies by Gunnal<sup>14</sup> but lower than the values of other researcher where they had used a cardiac sizer for measurement.<sup>19</sup> The present mean value was also lower than the values of other observers.<sup>21,26</sup> Though there was no direct relation between the diameter and the annular circumference of the same valve, generally with larger circumference the diameter was found to be longer. Usually the diameter and circumference of tricuspid annulus were higher than the mitral annulus and in living the diameter was marginally at the lower range.

The future implication of this study includes survey on larger samples, collection of data from female sex as well and comparison with radiological survey.

## REFERENCES

1. Standring S. *Grays Anatomy. The Anatomical Basis of Clinical Practice.*(40th ed.). Churchill Livingstone Elsevier 2008: 962-71.
2. Tatiana YW, Vaugh B, Hooker SP *et al.* Sedentary behaviours increase risk of cardiovascular disease mortality in men. *Med Sci Sports Exerc* 2010; 42: 879-85.
3. Du Plessis LA, Marchand P. The Anatomy of the mitral valve and its associated structures. *Thorax* 1964; 19: 221-7.
4. Menon RG, AlDelamie T, Vatliathu J *et al.* Paediatric valve replacement, 15 years experience in Oman. *Ind J Thorc Cardiovasc Surg* 2006; 22: 173-7.
5. Catherine OM, Lenehan A, Ginsburg V, *Textbook of valvular heart disease*, 2nd ed. 1999.
6. Rohilla A, Singh K, Chhabra S, Tricuspid valve morphometry: A new learning from cadavers. *Anat Physiol* 2015; 5: 185.
7. Bhandari S, Subramanyam K, Trehan N. Valvular heart disease diagnosis and management. *J Assoc Physc India* 2007; 55: 575-84.
8. Tanzi RY, Kreitti JM, Jamieson SW. Acquired valvular heart disease, *Essential Surgical Practice 3rd ed Oxford*: 1995; 865-6.
9. Ormiston JA, Shah P M, Tei C *et al.* Size and motion of the mitral valve annulus in man. *Circulation*.1981. *Am Heart Assoc* 1981; 64: 113-20.
10. Rollick C, Pittman M, Filly K *et al.* Mitral and aortic valve orifice area in normal subjects and in patients with congestive cardiomyopathy: Determination by two dimensional echocardiography. *Am J Cardiol* 1982; 49: 1191- 96.
11. Andrade NM, Tenios E, Viera RW *et al.* Coefficients of proportions of atrioventricular valves. An anatomical study of valvular segment of normal individual. *Rev Bras Cir Cardiovasc* 2005; 20: 255-60.
12. Skwarek M, Hreczecha J, Dudziak M. The morphology of the right atrioventricular valve in the adult human heart. *Folia Morphol* 2008; 67: 53-7.
13. Patil D, Mehta C, Prajapati P. Morphology of mitral valve in human cadavers. *Int'l J Cardiol* 2008; 7: 2.
14. Gunnal SA, Farooqui MS, Wabale RN. Study of mitral valve in human cadaveric hearts. *Heart News* 2012; 13: 132-35.
15. R Kalyani, M J Thej, K Prabhakar, TK Venkatesh, AK Thomas, J Kiran. Morphometric analysis of tricuspid valve: An indian perspective. *J Nat Sci Biol Med* 2012; 3: 147-51.
16. Pant P, Mukhia R, NK Haritha *et al.* Morphological and morphometrical analysis of mitral valve in maharashtra region: cadaveric study. *Indian J App Research* 2013; 3: 497-8.
17. Gupta C, Shetti VR, Manju BVM. Dimensions of the human adult mitral valve in the embalmed cadaver. *J Morphol Sci* 2013; 30 : 6-10.
18. Deopujari R, Sinha U, Athavale SA. Anatomy of mitral valve leaflets in adult indian cadavers. *Int'l J Morphol* 2013; 31: 1276-81.
19. Amgain K, Thakur SK, Virupaxi RD *et al.* Mitral valve size measurement in north karnataka by using cardiac sizer: A cadaveric study. *Arch Med Health Sci* 2013; 1: 105-8.
20. Mishra PP, Rao MP, Paranjape V *et al.* Morphometry of mitral valve. *Med J DY Patil Univ* 2014; 7: 625-30.
21. Dwivedi G, Mahadevan G, Jimenez D *et al.* Reference values for mitral and tricuspid annular dimensions using two-dimensional echocardiography. *Echo Res Pract* 2014; 1: 43-50.

- 
22. BR Harsha, KT Chandrashekhar. Cadaveric study on anterior and posterior papillary muscles of tricuspid valve. *Int'l J Anat Res* 2015; 3: 865-8.
  23. Rohilla A, Singh K, Rohilla J *et al*. Tricuspid valve morphometry: A new learning from cadavers. *Anat Physiol* 2015; 5: 185.
  24. Naick KD, C Sreekanth, K Thyagaraju. Morphometry of tricuspid valve in human fetal cadavers. *Int'l J Anat Res* 2015; 3: 1114-20.
  25. Ilankathir S. A cadaveric study on adult human heart valve annular circumference and its' clinical significance. *IOSR -J Dent Med Sci* 2015; 14: 60-4
  26. Roy S, Saha A. Mitral valve beyond classical view- A morphometric evaluation. *J Anat Soc Ind* 2016 ; 65: 20-3.
  27. Mohammadi S, Hedjazi A, Sajjadian M *et al*. Study of the normal heart size in northwest part of iranian population: A cadaveric study. *J Cardio Vasc Thorac Res* 2016; 8: 119-25.