

# PATTERN OF VISUAL FIELD DEFECTS IN NEWLY DIAGNOSED PRIMARY OPEN ANGLE GLAUCOMA PATIENTS ATTENDING TERTIARY CARE HOSPITAL, KATHMANDU, NEPAL

*Singh P, Rijal AP*

Department of Ophthalmology, Nepal Medical College and Teaching Hospital, Attarkhel, Gokarneshwor-8, Kathmandu, Nepal

## ABSTRACT

The purpose of this study was to evaluate the location and pattern of visual field defects as measured by Humphrey Field Analyzer (HFA 24-2) in newly diagnosed primary open angle glaucoma (POAG) attending tertiary care hospital. This was a cross sectional, descriptive study. One hundred and four eyes of 52 patients who fulfilled the inclusion criteria during one year were included. They were classified as mild, moderate and severe glaucoma according to severity. Paracentral scotoma in superotemporal and superonasal region was the most frequent visual field defect observed in mild glaucoma. Superior arcuate defect and double arcuate defect was commonly seen among moderate and severe stages of POAG respectively. There was a significant association between severity of glaucoma and pattern of visual field defect ( $p=0.000$ ). The superior hemifield was affected twice more than the inferior hemifield in newly diagnosed cases of POAG.

## KEYWORDS

Primary open angle glaucoma, visual field defect, Nepal

## CORRESPONDING AUTHOR

Dr. Pranisha Singh,  
Assistant Professor  
Department of Ophthalmology,  
Nepal Medical College Teaching Hospital,  
Attarkhel, Gokarneshwor-8, Kathmandu, Nepal  
Email: prani\_s@hotmail.com  
Orcid No: <https://orcid.org/0000-0001-8459-6515>  
DOI: <https://www.doi.org/10.3126/nmcj.v22i4.34181>

## INTRODUCTION

Glaucoma is the second leading cause of blindness globally.<sup>1,4</sup> It is a leading cause of preventable blindness worldwide and is characterized by irreversible optic nerve damage and progressive visual field (VF) loss.<sup>5</sup> Patients are generally asymptomatic until late anatomical and functional damage of the optic nerve.<sup>7</sup> HFA allows the functional evaluation of the optic nerve and is used to diagnose, determine the severity and monitor progression of the disease.<sup>7,8</sup> Visual field defects are observed in HFA when about 40% of the retinal ganglion fibers have been damaged.<sup>9</sup> It does not help in early diagnosis, since the loss of fibers of the nerve fiber layer of the retina precedes the appearance of visual field defects.<sup>10,11</sup> The most frequent initial defect is the nasal step, which may or may not be accompanied by paracentral scotoma.<sup>12,13</sup> Visual field defects near fixation have a greater impact on the level of function compared with peripheral changes, even at an early stage of glaucoma.<sup>14,15</sup> It is generally taught that initial glaucomatous VF abnormalities frequently occur in the periphery with relative preservation of the central field. But in some patients the initial defect may be quite centrally located. Therefore, the aim of this study was to evaluate various pattern and location of visual field defects in patients with POAG across different severity level as no such study has been reported in our setting.

## MATERIALS AND METHODS

The study was conducted in outpatient department (OPD) of Ophthalmology at Nepal Medical College Teaching Hospital (NMCTH) from January 2019 to December 2019. One hundred and four eyes of 52 cases of POAG were studied. Sample size was taken using the formula Finite size  $n = n_0 / 1 + n_0 / N = 4806 / 1 + 4806 / 50 = 4806 / 1 + 96.12 = 4806 / 97.12 = 49$ . This was a descriptive, cross sectional hospital-based study.

Patients with glaucomatous optic disc changes like vertically elongated optic cups, asymmetry of cup disc ratio (CDR) >0.2, thinning or notching of Neuro Retinal Rim (NNR), nerve fibre layer defect, Intraocular pressure (IOP) > 20mmHg were included in the study. Patients with secondary open angle glaucoma, who had undergone glaucoma surgery and patients with neurological diseases that could cause visual field defect were excluded from the study. Informed consent was taken from each patient. Ethical clearance was taken from Nepal Medical College- Institutional Review Committee (NMC-

IRC). All patients received an ophthalmic examination including visual acuity, anterior segment by slit lamp examination, intraocular pressure measurement by applanation tonometry, central corneal thickness measurement by pachymetry, gonioscopy with single mirror gonioscopes and evaluation of the optic discs with +90 Diopter lens. All 52 patients were examined with Humphrey visual field using 24-2 Swedish Interactive Threshold Algorithm (SITA) threshold program of both eyes. Only the reliable (fixation losses <20%, false positives and false-negatives <33%) visual fields were included in the study. In case of unreliable fields, the test was repeated after few days. Then the more reliable field was selected for analytical purposes.

Visual fields were considered to be abnormal according to Hodapp-Parrish-Anderson criteria.<sup>16</sup>

### Perimetry

- A. A glaucoma hemi field test (GHT) outside normal limits
- B. Pattern standard deviation (PSD)  $p < 5\%$  or
- C. Three adjacent non-edge points  $p < 5\%$  in the pattern deviation probability plot of which at least one point was  $p < 1\%$  and all points were on the same side of the horizontal meridian.

For this study, we defined POAG as mild, moderate and severe.

**Mild POAG** as a vertical CDR  $\leq 0.65$ , mild VF defect not within  $10^\circ$  of fixation (Mean Deviation (MD) better than -6dB on HFA 24-2).

**Moderate POAG** as a vertical CDR 0.7 to 0.85, moderate VF defect not within  $10^\circ$  of fixation (MD between -6 and -12 dB on HFA 24-2).

**Severe POAG** as a vertical CDR  $\geq 0.9$ , VF defect within  $10^\circ$  of fixation (MD worse than -12 dB on HFA 24-2).<sup>17</sup>

Data was collected in research proforma. Data entry and statistical analysis were done using SPSS version 16. The chi-square test was used to find the association between categorical variables. P value < 0.05 was considered significant.

## RESULTS

A total of 104 eyes of 52 patients with newly diagnosed case of POAG were evaluated in the study. Twenty-nine (55.8%) of the cases were male while 23 (44.2%) were female. The mean age of study subjects was  $54.75 \pm 15.62$  years

**Table 1: Glaucoma parameters and association between VF defect.**

Variables	Mean± SD	P value
Age	54.75 ± 15.62	0.05
Vertical CDR	0.64 ± 0.12	0.000
IOP	20.10 ± 3.28	0.42
CCT	532.18 ± 35.12	0.05
HFA MD	-9.93 dB ± 8.21	0.000
HFA PSD	5.50 dB ± 3.54	0.26
Test time	6.57 ± 1.43	0.20

(range 30-87 years). There was no significant association between age and severity of cupping (p=0.67) but there was significant association between age and visual field defect (p=0.05) (Table-1). Tibeto-Mongolian was 33 (63.5%) while Indo-Aryan was 19 (36.5%). About 42 (80.8%) were asymptomatic and 10 (19.2%) had headache. Among 42 asymptomatic, 23 cases

**Table 2: Pattern and location of VF defect in newly diagnosed POAG**

Pattern and location of VF defect	N (%)
Superonasal paracentral scotoma	10 (9.6%)
Superotemporal paracentral scotoma	10 (9.6%)
Inferonasal paracentral scotoma	8 (7.7%)
Inferotemporal paracentral scotoma	6 (5.8%)
Superior arcuate scotoma	28 (26.9%)
Inferior arcuate scotoma	7 (6.7%)
Double arcuate scotoma	7 (6.7%)
Superior nasal step	5 (4.8%)
Central scotoma	4 (3.8%)
No scotoma	19 (18.3%)

were of mild glaucoma, 16 were moderate and 3 were severe glaucoma. Out of 10 symptomatic, 6 cases were mild and 4 were moderate glaucoma (p=0.68).

Out of 52 patients, 32 (61.6%) had refractive error and 20 (38.5%) had no refractive error. Twelve (23.1%) had simple myopia, 7 (13.5%) had simple myopic astigmatism, 3 (5.8%) had compound myopic astigmatism, 5 (9.6%) had simple hypermetropia, 2 (3.8%) had simple hypermetropic astigmatism and 3 (5.8%) had compound hypermetropic astigmatism. There was no significant association between refractive error and severity of cupping and VF defect (p=0.12, p=0.56).

In this study, 15 (28.8%) were hypertensive patients, 4 (7.7%) were diabetic, 7 (13.5%) were both hypertensive and diabetic and 2 (3.8%) were of chronic obstructive pulmonary disease and 46.2% had no systemic diseases. There was a significant association between systemic disease and severity of cupping and VF defect (p=0.000, p=0.005).

The mean IOP was 20.10±3.28 mmHg and it ranged from 14-30 mmHg. The mean CCT was 532.18 µm ± 35.12 ranged from 435 to 630µm. There was a significant association between IOP and CCT (p=0.003). There was a significant association between IOP and severity of cupping (p=0.03) and no association between VF defect (p=0.42). Whereas there was significant association between CCT and VF defect (p=0.052) and no association with severity of cupping (p=0.73) (Table 1).

The mean cup disc ratio was 0.64:1 ± 0.12, ranged from 0.5:1 to 0.95:1. According to cup disc ratio, mild glaucoma (CDR ≤0.65) was seen in 62 (59.6%) eyes, moderate glaucoma (CDR 0.7 to 0.85) was seen in 34 (32.7%) and severe glaucoma (CDR ≥ 0.9) was seen in 8 (7.7%) at the time of diagnosis. There was a significant association between CDR and pattern of visual field defect and HFA MD (p=0.000 and p=0.003) respectively (Table 1). But there was no significant association between CDR and

**Table 3: Pattern of VF defect in POAG across different severity**

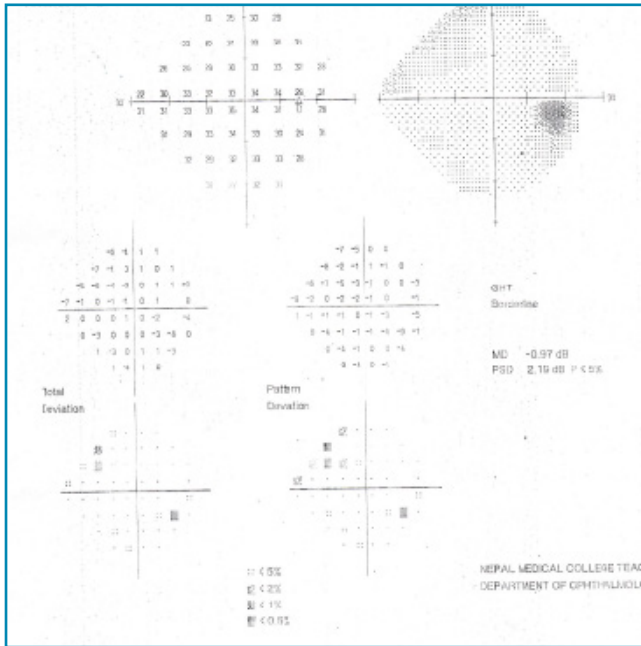
Severity of glaucoma	Paracentral scotoma	Superior arcuate scotoma	Inferior arcuate scotoma	Double arcuate scotoma	Superior nasal step	Central scotoma	No scotoma	Total	p value
Mild	26	16	1	0	4	1	14	62	
Moderate	8	9	6	4	1	1	5	34	
Severe	0	3	0	3	0	2	0	8	
<b>Total</b>	34	28	7	7	5	4	19	104	0.000

Significant association between severity of glaucoma and pattern of VF defect (p=0.000).

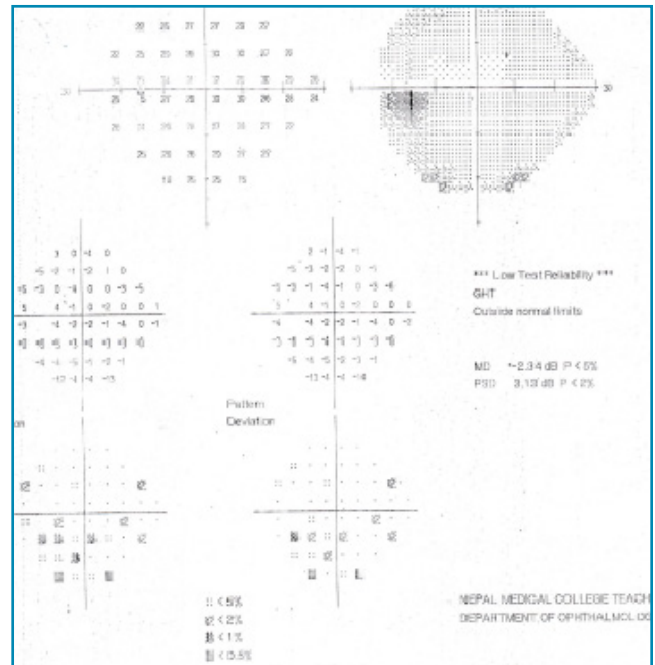
**Table 4: Association between vertical CDR and HFA MD**

Severity of glaucoma	MD <-6 dB	MD -6 to -12 dB	MD > -12 dB	Total	P value
Mild (CDR<0.65:1)	27	24	11	62	
Moderate (CDR 0.7 to 0.85:1)	13	6	15	34	0.003
Severe (CDR> 0.9:1)	1	1	6	8	
<b>Total</b>	<b>41</b>	<b>31</b>	<b>32</b>	<b>104</b>	


Significant association between vertical CDR and HFA MD (p=0.003)




**Fig. 1: HFA showing Superonasal paracentral scotoma**



**Fig. 3: HFA showing Inferotemporal paracentral scotoma**



**Fig. 2: HFA showing Superotemporal paracentral scotoma**



**Fig. 4: HFA showing Superior arcuate scotoma**

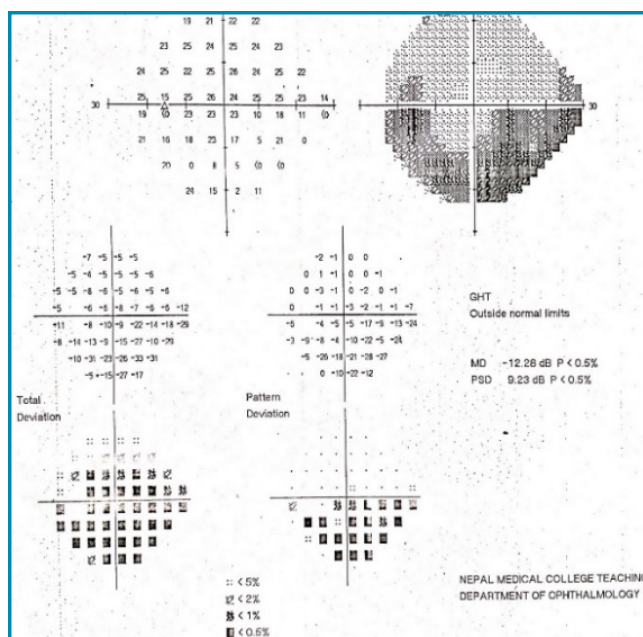


Fig. 5: HFA showing **Inferior arcuate scotoma**

HFA GHT and HFA PSD ( $p=0.69$  and  $p=0.16$ ) respectively.

Out of 104 eyes which were studied, 67 (64.4%) had thinning of NNR, 21 (20.2%) had notching and 16 (15.4%) had intact NNR. The most common site for NNR loss was inferior rim 35 (33.7%) followed by bipolar rim 22 (21.2%), superior rim 16 (15.4%), inferotemporal 9 (8.7%), superotemporal 3 (2.9%), temporal 2 (1.9%) and nasal 1 (1%). There was a significant association between rim loss and stage of glaucoma ( $p=0.000$ ). Out of 16 intact NNR, 5 eyes had visual field defect on HFA and out of 67 thinning NNR, 8 had no visual field defect. There was significant association between site of rim loss and pattern of visual field defect and HFA GHT ( $p=0.000$ ,  $p=0.033$ ) respectively. But there was no significant association between site of rim loss and HFA MD and HFA PSD ( $p=0.38$ ,  $p=0.77$ ).

The most common pattern of visual field defect in this study was paracentral scotoma which was seen in 34 (32.7%) eyes. Among paracentral both superonasal and superotemporal paracentral defect was seen in 10 eyes (9.6%) each whereas inferonasal paracentral in 8 (7.7%) and inferotemporal in 6 (5.8%). Superior arcuate scotoma in 28 (26.9%), inferior arcuate scotoma in 7 (6.7%), double arcuate scotoma in 7 (6.7%), Superior nasal step in 5 (4.8%), central scotoma in 4 (3.8%) and 19 (18.3%) had no VF defect (Table 2). In the early glaucoma, paracentral scotoma was the most frequent visual field defect followed by superior arcuate defect and superior nasal step. In moderate glaucoma, superior arcuate defect was common




Fig. 6: HFA showing **double arcuate scotoma**

followed by paracentral scotoma and in severe glaucoma double arcuate and superior arcuate scotoma was common. There was a significant association between severity of glaucoma and pattern of visual field defect ( $p=0.000$ ) (Table-3). Superior defect was seen in 50.9% whereas inferior was seen in 20.2%. In this study visual field defects showed superior defects to be twice as common as inferior defects.

The average mean deviation (MD) of HFA was  $-9.93 \text{ dB} \pm 8.21$ , ranged from  $-32.50$  to  $-0.39$  dB. Out of 104 eyes 41 (39.4%) had MD  $< -6$  dB, 31 (29.8%) had between  $-6$  to  $-12$  dB and 32 (30.8%) had  $> -12$  dB. There was a significant association between HFA MD severity and pattern of visual field defect ( $p=0.000$ ). In this study the mean pattern standard deviation (PSD) of HFA was  $5.50 \text{ dB} \pm 3.54$  ranged from 1.29 dB to 15.02 dB. It showed no significant association between HFA PSD and pattern of VF defect ( $p=0.26$ ).

Out of 104 eyes 76 (73.1%) had outside normal limit GHT, 15 (14.4%) had within normal GHT and 13 (12.5%) had borderline GHT. There was a significant association between HFA GHT and pattern of VF defect ( $p=0.000$ ).

The average test time was  $6.57 \pm 1.43$ , ranged from 4.14 to 11.48 minutes. There was no significant association between test time and pattern of visual field defect ( $p=0.20$ ).

## DISCUSSION

Glaucoma is a disease that initially affects the peripheral vision. Often, it is difficult to

recognize that peripheral vision is changing during normal daily activities because the deficits can be subtle and one eye can compensate for the other. As the disease progresses, more and more of the peripheral vision is lost until eventually, in very late and advanced disease, the central vision is also affected. Sometimes there are patients with glaucoma who have their central vision affected early in the course of the disease which is another reason that formal visual field testing is so important. In many individuals who are developing the disease, changes in the optic nerve or retinal nerve fiber layer are the initial signs of loss.<sup>18,19</sup> Perimetric damage, when present, is thought to signal that significant structural damage has occurred.<sup>18,20-22</sup> Visual field assessment is mandatory for the diagnosis and management of POAG.

This study was carried out to identify the pattern and location of visual field defect in newly diagnosed cases of POAG. In our study paracentral scotoma was seen in 34 (32.7%) eyes. Among paracentral scotoma both superonasal and superotemporal paracentral scotoma (Fig. 1, 2) was seen in 10 eyes (9.6%) whereas inferonasal paracentral in 8 (7.7%) and inferotemporal paracentral scotoma (Fig. 3) was found in 6 (5.8%). Superior arcuate scotoma (Fig. 4) in 28 (26.9%), inferior arcuate scotoma (Fig. 5) in 7 (6.7%), double arcuate scotoma (Fig. 6) in 7 (6.7%), superior nasal step in 5 (4.8%), central scotoma in 4 (3.8%) and 19 (18.3%) had no VF defect. Out of 19 who had normal VF, 14 eyes were of mild and 5 eyes were of moderate glaucoma. This may be because of the fact that patients with early POAG may have normal visual fields on HFA and it has been estimated that 40% of ganglion cells need to be damaged before a field defect becomes apparent.

Our study results suggest that paracentral scotoma in superotemporal and superonasal region was the most common visual field defect seen in early stage of POAG. Superior arcuate defect and double arcuate defect was commonly seen among moderate and severe stage of POAG respectively. There was a statistically significant association between severity of glaucoma and pattern of VF defect ( $p=0.000$ ).

Similarly, in a study by Lichter *et al*,<sup>23</sup> a consecutive series of POAG patients was evaluated to determine the earliest glaucomatous visual field defect. Paracentral defects and isolated nasal steps were found to occur early in the pattern of glaucomatous field loss. Another study conducted by Nascimento

VC *et al*<sup>24</sup> found that in the early POAG group, the nasal superior step was the most frequent visual field defect, followed by paracentral scotoma and inferior nasal step as evaluated by SITA strategy and the superior hemifield comprises most of the defects. A study done by Alipanahi *et al*<sup>25</sup> showed that the most common visual field defect was nasal and peripheral scotoma beyond 20° of fixation at the Tabriz, Nasal and arcuate visual field defect at Graz patients. Using automated perimetry the distribution of visual field loss in 40 chronic open angle glaucoma eyes was found to be predominantly in the nasal, supranasal and superotemporal regions in O'Brien C and Schwartz B study.<sup>26</sup> Similarly, Goldberg I<sup>27</sup> study found that paracentral scotoma and nasal step defects were the earliest visual field changes in POAG. Lewis *et al*<sup>28</sup> study found superior arcuate scotoma and superior nasal steps were the most common visual field defects in both POAG and secondary glaucoma. Similar to our study, Sharma *et al*<sup>29</sup> found that among the most common causes of visual defect in glaucoma, the most common was paracentral scotoma (44.4%) followed by arcuate scotoma (23.4%).

The inferotemporal segment of the neuroretinal rim is typically most susceptible to early damage in POAG,<sup>30</sup> which explains the greater propensity toward defects in the superior visual field in the early stages of the disease.<sup>31,32</sup> In our study, the most common site for NNR loss was inferior rim 35 (33.7%) followed by bipolar rim 22 (21.2%), superior rim 16 (15.4%), inferotemporal 9 (8.7%), superotemporal 3 (2.9%), temporal 2 (1.9%) and nasal 1 (1%). In this study the superior hemifield was affected twice more than the inferior hemifield. Superior defect was seen in 50.9% whereas inferior was seen in 20.2%, double arcuate was seen in 6.7%, central in 3.8% and normal in 18.3%. Similarly, Nicholas SP *et al*<sup>33</sup> showed that superior defects to be twice as common as inferior defects.

Schiefer *et al*<sup>34</sup> found that glaucomatous VFD loss occurred more frequently in the upper than in the lower hemifield, with a typical retinal nerve fiber-related pattern and a preference of the nasal step region. More than 50% of the eyes with predominantly mild to moderate glaucomatous field loss showed defective locations in the immediate superior paracentral region within an eccentricity of 3°.

In a study by Han *et al*<sup>35</sup> found that POAG cases had the greatest rate of central visual field damage (52.38%), followed by acute angle-closure glaucoma (47.6%), the central visual field of CACG is the least suffered (22.6%). The nasal area was the most commonly

involved area in the early stage of glaucoma. But in our study only 4 patients had central field defect, among them 1 was of mild stage, 1 was of moderate and 2 were of severe stage of glaucoma. Nasal area was not commonly involved in our study. It was seen only in 5 eyes (4.8%). Out of 5, 4 eyes were of mild glaucoma that had superior nasal VF defect and 1 was of moderate glaucoma.

The temporal wedge defect was very rare in mild glaucoma, probably because the medial fibers were the last to be injured and its incidence, even in moderate and severe glaucoma, was low. These fibers correspond to the rhyme of the nasal quadrant of the optic disc, some found that when compared to the evaluation of the other regions of the disc, the evaluation of the nasal region is less important in detecting the glaucomatous optic nerve.<sup>36</sup> In our study also temporal wedge defect was not seen in a single case.

In our study mild glaucoma (CDR  $\leq$ 0.65) was seen in 62 (59.6%) eyes, moderate glaucoma (CDR 0.7 to 0.85) was seen in 34 (32.7%) and severe glaucoma (CDR  $\geq$  0.9) was seen in 8 (7.7%) at the time of diagnosis. There was a significant association between CDR and pattern of visual field defect and HFA MD

( $p=0.000$  and  $p=0.003$ ) (Table 4) respectively. About 80.8% were asymptomatic and only 19.2% were symptomatic. Among 42 asymptomatic, 23 cases were of mild glaucoma, 16 were moderate and 3 were severe glaucoma. The cases were mainly diagnosed coincidentally when they came for different purpose of eye examination. Therefore, glaucoma awareness among the population is needed to prevent from blindness.

In conclusion, our study suggests that Paracentral scotoma in superotemporal and superonasal region was the most frequent visual field defect observed in mild glaucoma. Superior arcuate defect and double arcuate defect was commonly seen among moderate and severe stages of newly diagnosed POAG respectively. The limitation of this study is that our results are derived from cross sectional study. Furthermore, longitudinal studies are needed with large sample size to overcome the limitation.

## ACKNOWLEDGMENT

We express our gratitude towards patients for their kind cooperation and resident doctors for their help during this study.

## REFERENCES

1. Quigley H, Broman A. The number of people with glaucoma worldwide in 2010 and 2020. *Br J Ophthalmol* 2006; 90: 262-67.
2. Pascolini D, Mariotti S. Global estimates of visual impairment: 2010. *Br J Ophthalmol* 2012; 96: 614-18.
3. Kass M, Heuer D, Higginbotham E. The Ocular Hypertension Treatment Study: a randomized trial determines that topical ocular hypotensive medication delays or prevents the onset of primary open-angle glaucoma. *Arch Ophthalmol* 2002; 120: 701-13.
4. Leske M, Heijl A, Hussein M, et al. Factors for glaucoma progression and the effect of treatment: the early manifest glaucoma trial. *Arch Ophthalmol* 2003; 121: 48-56.
5. Varma R, Lee PP, Goldberg I, Kotak S. An assessment of the health and economic burdens of glaucoma. *Am J Ophthalmol* 2011; 52: 515-22.
6. Quigley HA. Number of people with glaucoma worldwide. *Br J Ophthalmol* 1996; 80: 389-93.
7. Mikelberg FS, Drance MS. Glaucomatous visual field defects. In: Ritch R, Shields MB, Krupin T. The glaucomas. 2nd ed. St. Louis, Mosby; 1996. vol 2, p.523-37.
8. Chen YF, Wang TH, Hung PT. Automated perimetry in primary open-angle glaucoma. *J Formos Med Assoc* 1997; 96: 441-5.
9. Quigley HA, Addicks EM, Green WR. Optic nerve damage in human glaucoma. Quantitative correlation of nerve fiber loss and visual field defect in glaucoma, ischemic neuropathy, papilledema, and toxic neuropathy. *Arch Ophthalmol* 1982; 100: 135-46.
10. Quigley HA, Dunkelberger GR, Green WR. Chronic human glaucoma causing selectively greater loss of large optic nerve fibers. *Ophthalmol* 1988; 95: 357-63.
11. Sommer A, Katz J, Quigley HA, et al. Clinically detectable nerve fiber atrophy precedes the onset of glaucomatous field loss. *Arch Ophthalmol* 1991; 109: 77-83.
12. Hart WM Jr, Becker B. The onset and evolution of glaucomatous visual field defects. *Ophthalmol* 1982; 89: 268-79.
13. Werner EB, Drance SM. Early visual field disturbances in glaucoma. *Arch Ophthalmol* 1977; 95: 1173-5.
14. Fujita K, Yasuda N, Oda K, Yuzawa M. Reading performance in patients with central visual field disturbance due to glaucoma. *Nippon Ganka Gakkai Zasshi* 2006; 110: 914-18.
15. Coexkelbergh TR, Brouwer WH, Cornelissen FW, et al. The effect of visual field defects on driving performance: a driving simulator study. *Arch Ophthalmol* 2002; 120: 1509-16.

16. Katz J, Sommer A, Gaasterland DE, Anderson DR. Comparison of analytic algorithms for detecting glaucomatous visual field loss. *Arch Ophthalmol* 1991; 109: 1684-89.
17. Mills RP, Budenz DL, Lee PP *et al.* Categorizing the stage of glaucoma from pre-diagnosis to end-stage disease. *Am J Ophthalmol* 2006; 141: 24-30.
18. Quigley HA, Dunkelberger GR, Green WR. Retinal ganglion cell atrophy correlated with automated perimetry in human eyes with glaucoma. *Am J Ophthalmol* 1989; 107: 453-64.
19. Medeiros FA, Alencar LM, Zangwill LM, *et al.* Prediction of functional loss in glaucoma from progressive optic disc damage. *Arch Ophthalmol* 2009; 127: 1250-56.
20. Medeiros FA, Lisboa, R, Weinreb RN, *et al.* Retinal ganglion cell count estimates associated with early development of visual field defects in glaucoma. *Ophthalmol* 2013; 120: 736-44.
21. Hood DC, Kardon RH. A framework for comparing structural and functional measures of glaucomatous damage. *Prog Retin Eye Res* 2007; 26: 688-710.
22. Harwerth RS, Carter-Dawson L, Smith EL III, *et al.* Neural losses correlated with visual losses in clinical perimetry. *Invest Ophthalmol Vis Sci* 2004; 45: 3152-60.
23. Lichter PR, Standardi CL. Early Glaucomatous Visual Field Defects and their Significance to Clinical Ophthalmology. *Third International Vis Field Symposium* 1978; 19: 111-8.
24. Nascimento VC, Kasahara N, Cohen R, Almeida GV, Mandia C, Paolera MD. Location and frequency of visual field defects as measured by SITA (Swedish Interactive Threshold Algorithm) strategy in primary open angle glaucoma. *Arq Bras Oftalmol* 2005; 68: 661-5.
25. Alipanahi R, Sayyehmelli M, Ghojzadeh L, Sayyehmelli S. Common visual field defect in the open angle glaucoma eyes. *Rawal Med J* 2008; 33: 98-100.
26. O'Brien C, Schwartz B. The Visual Field in Chronic Open Angle Glaucoma: The Rate of Change in Different Regions of the Field. *Eye* 1990; 4: 557-62.
27. Goldberg I. Optic Disc and Visual Field Changes in Primary Open Angle Glaucoma. *Australian J Ophthalmol* 1981; 9: 223-29.
28. Lweis RA, Phelps CD. A Comparison of Visual Field Loss in Primary Open Angle Glaucoma and the Secondary Glaucoma. *Ophthalmologica* 1984; 189: 41-48.
29. Sharma K, Sharma RL, Chaudhary KP, Gupta RK. Retrospective analysis of types of visual field defects (Octopus 900 perimeter-based study) at Shimla Hills. *Trop J Med Research* 2017;20; 149-54.
30. Jonas JB, Fernandez MC, Sturmer J. Pattern of glaucomatous neuroretinal rim loss. *Ophthalmol* 1993; 100; 63- 8.
31. Drance SM. The glaucomatous visual field. *Invest Ophthalmol* 1972; 11; 85-96.
32. Hart WM, Becker B. The onset and evolution of glaucomatous visual field defects. *Ophthalmol* 1982; 89; 268-79.
33. Nicholas SP, Werner EB. Location of early glaucomatous visual field defects. *Can J ophthalmol* 1980; 15: 131-3.
34. Schiefer U, Papageorgiou E, Sample PA. Spatial pattern of Glaucomatous Visual Field Loss Obtained with Regionally Condensed Stimulus arrangements. *Invest Ophthalmol Vis Sci* 2010; 51: 5685-89.
35. Han F, Yuan YS. Characteristics of visual field defects in primary angle closure glaucoma. *Zhonghua Yan Ke Za Zhi* 2009; 45: 14-20.
36. Jonas JB, Budde WM. Is the nasal optic disc sector important for morphometric glaucoma diagnosis? *Br J Ophthalmol* 2002; 86: 1232-5.